

**PATIENT**

Jax Sysum

**SPECIES**

Canine

**BREED**

Boxer

**SEX**

Male Neutered

**AGE**

7.7 years

**WEIGHT**

79.6lbs

**INTERPRETED BY**

Maggie Machen Lamy,  
DVM, DACVIM  
(Cardiology)

**IMAGING PERFORMED BY**

Loetitia Saint-Jacques,  
LVT

**HOSPITAL NAME**

Four Paws Animal  
Clinic

**REFERRING VET**

Dr. Lester

**INVOICE**

47648

**DATE**

4/22/26

**PRESENTING CLINICAL SIGNS**

History: Work up for potential gingival hyperplasia reduction. BW and ECG ran in clinic: ventricular arrhythmia noted. O very concerned about anesthetic risk. No murmur, no arrhythmia noted today. Not symptomatic. Gingival hyperplasia. BLOOD PRESSURE: L lateral recumbency, #4 cuff, R rear (BP MAP HR) 149/93 110 176, 158/95 122 183, 152/83 106 173, 129/79 101 169, 147/75 97 168, 127/78 94 166. Heartgard, Nexguard only typically. Sedated with Gabapentin and Trazodone.  
-ECG (Idexx): showed ventricular arrhythmias (not quantified).  
-Abnormal PE/Chem/CBC/UA Results (4.18.26): Lymphocytes 0.268, otherwise WNL, including BNP.

**ELECTROCARDIOGRAPHIC FINDINGS**

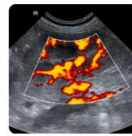
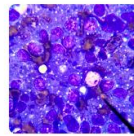
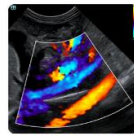
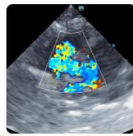
A six lead ECG is available at 25mm/s; 10mm/mV. The average heart rate is 120bpm. The rhythm is sinus in origin, with a p for every QRS complex and vice versa. The P wave morphology is positive with a normal dimension. Normal PR. The QRS morphology is positive with normal dimension. MEA is normal. No VPCs, APCs, pauses or other dysrhythmias observed.  
ECG diagnosis: Normal sinus rhythm.

**ECHOCARDIOGRAM FINDINGS**

2D, m-mode, color flow and doppler imaging is available. Normal mitral valve leaflets with no obvious prolapse into the left atrial lumen. No mitral regurgitation is identified. Normal left atrial dimension. Normal LV diameter with normal myocardial function. The tricuspid valve appears subjectively normal, and there is trace tricuspid regurgitation. The right heart appears normal (subjective). No overt evidence of pulmonary arterial hypertension. The pulmonic and aortic valves are normal in morphology and mobility. No aortic abnormalities identified with a normal aortic outflow velocity, laminar flow. Normal pulmonic outflow velocities. No aortic or pulmonic insufficiency. No pericardial or pleural effusion noted. No cardiac tumors observed.

**CARDIAC CHART**

CANINE CARDIAC PARAMETERS	MR VMAX (m/s)	TR VMAX (m/s)	LA/AO (Boon method)	LA/AO (Heart Base; Swe)	FS (%)	EF (%)	EPSS (cm)
<b>NORMAL PARAMETER</b>	4.5-5.5	<2.7	1.3	<1.6	28-40	40-100	<0.6
<b>PATIENT</b>	NA	NM	NM	1.2	29	50	0.6
CANINE CARDIAC PARAMETERS	HR (BPM)	AV VMAX (m/s)	PV MAX (m/s)	BODY WEIGHT (kg)	LA 2D short axis Base view (cm)	LVIDd Avg; 2D and m-mode short axis (cm)	LVIDs Avg; 2D and m-mode short axis (cm)
<b>NORMAL PARAMETER</b>	50-100	0.7-1.7	0.7-1.6	BELOW	BELOW	BELOW	BELOW
<b>PATIENT</b>	NM	1.4	0.8	36.1	2.5	3.8	2.7
*Normal chamber parameters expressed as a mean value (SD)				3	1.27 (5.3)	2.46 (2.46)	1.36 (5.5)
<b>BODY WEIGHT DEPENDENT PARAMETERS</b>				5	1.40 (4.5)	2.74 (5.2)	1.60 (4.7)
*Note: All measurements based upon multi-modal images and methods. An average value is reported.				10	1.50 (3.8)	3.27 (3.5)	2.06 (3.1)
				15	1.83 (2.0)	3.71 (2.4)	2.43 (2.1)
				20	2.02 (1.9)	4.14 (2.2)	2.80 (2.0)
				25	2.18 (2.4)	4.48 (2.9)	3.10 (2.5)
Adapted from June Boon, Veterinary Echocardiography, 1998				30	2.33 (3.3)	4.83 (3.9)	3.39 (3.4)



**PATIENT**

Jax Sysum

Rishniw M and Hollis NE, J Vet Intern Med 2000; 14:429-435	35	2.48 (4.3)	5.17 (5.0)	3.69 (4.5)
Hansson et al, Vet Rad and Ultrasound 2002	40	2.62 (5.2)	5.48 (6.1)	3.96 (5.4)
Bonagura et al. Echocardiography: principles of interpretation, Vet	50	2.88 (7.1)	6.07 (8.3)	4.46 (7.4)

**SPECIES**

Canine

**INTERPRETATION OF THE FINDINGS & FURTHER RECOMMENDATIONS**

Overtly normal cardiac structure and function with no abnormalities identified. The systolic function appears intact, and the right heart is subjectively normal.

**BREED**

Boxer

The recorded ECG is normal, with no ventricular premature contractions (VPCs) seen. That said, the previous evaluation did confirm their presence. VPCs are generated from abnormal conductive or fibrotic tissue in the ventricles of the heart muscle, and even frequent single VPCs will often cause no clinical signs in dogs. When sustained however, ventricular tachycardia can lead to symptoms such as lethargy and collapse.

**SEX**

Male Neutered

VPCs are a very non-specific finding. They can be primary in origin (such as ARVC), be secondary to significant cardiac disease (not present in this study) or be extra-cardiac in origin, i.e., due to pain, stress, inflammation, cancer, GI disease, DIC/sepsis, etc. In a 7-year-old Boxer with presumably rare VPCs, ARVC is possible, with the most common age of onset is 6-8y. ARVC can occur with or without systolic dysfunction or structural issues; however, this should be monitored going forward for any progressive changes. Recommend rule out other differentials for ectopy through AUS, tick titers, troponin, etc. Unfortunately, there is always an elevated risk for collapse and sudden death in any arrhythmic patient, and even on medications this risk unfortunately still persists. ARVC carries a HIGHLY variable prognosis, with some dogs able to remain asymptomatic for extended periods of time, and others developing exercise intolerance, syncopal episode, and refractory arrhythmias/sudden death imminently.

**AGE**

7.7 years

Based strictly upon the amount of arrhythmia present on the available ECG (none) in this asymptomatic dog, anti-arrhythmic therapy is not clearly indicated. A holter monitor is recommended as the next step to allow monitoring of the rhythm throughout 24 hours of a normal day and help determine if treatment is indicated.

**WEIGHT**

79.6lbs

Fish oil supplementation is recommended for dogs with arrhythmias (1000mg of omega 3 and 6 once to twice daily). Mild activity/stress restriction is advised.

**INTERPRETED BY**

Maggie Machen Lamy,  
DVM, DACVIM  
(Cardiology)

**IMAGING PERFORMED BY**

Loetitia Saint-Jacques,  
LVT

**HOSPITAL NAME**

Four Paws Animal  
Clinic

Monitor at home for collapse, exercise intolerance, and/or lethargy. If a holter monitor is elected, this will dictate whether therapy is needed and follow up protocol. I would not recommend anesthesia until the results are available if elected. If declined, an ECG should be monitored during general anesthesia and lidocaine administered in the event of sustained VT or malignant arrhythmias. Avoid stimulants such as atropine or glycopyrrolate unless indicated.

**REFERRING VET**

Dr. Lester

**INVOICE**

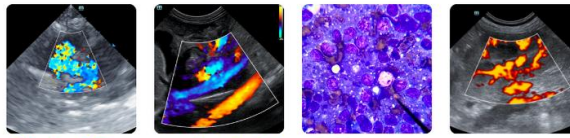
47648

No cardiac medications are indicated at this time. Monitor for any development of cough, labored breathing or exercise intolerance.

**DATE**

4/22/26

Anesthetic risk is considered moderately elevated. Avoid ketamine, telazol, Dexdomitor (or other alpha-2 agonists) and acepromazine. Recommend having lidocaine CRI available for use in the event of worsening ventricular arrhythmias under anesthesia (CRI 50—75mcg/kg/min).



**PATIENT**

Jax Sylum

**SPECIES**

Canine

**BREED**

Boxer

**SEX**

Male Neutered

**AGE**

7.7 years

**WEIGHT**

79.6lbs

**INTERPRETED BY**

Maggie Machen Lamy,  
DVM, DACVIM  
(Cardiology)

**IMAGING PERFORMED BY**

Loetitia Saint-Jacques,  
LVT

**HOSPITAL NAME**

Four Paws Animal  
Clinic

**REFERRING VET**

Dr. Lester

**INVOICE**

47648

**DATE**

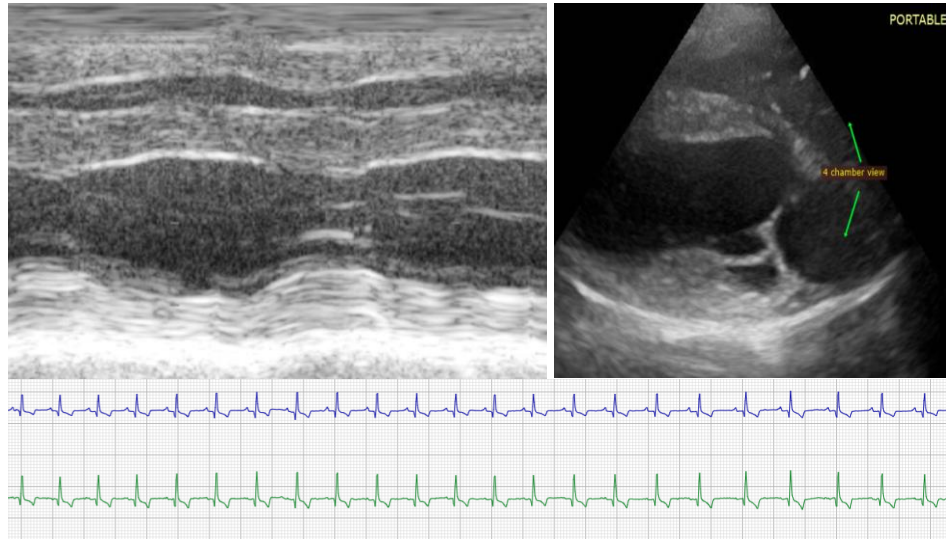
4/22/26

**PLAN**

Holter monitor recommended. Consider systemic evaluation as discussed. If a holter is declined, recommend a recheck ECG is recommended in 2-3 months (sooner if any collapse episodes occur).

A recheck echocardiogram is recommended every 6-12 months to screen for development of dilation/dysfunction.

**IMAGES**



**The information and recommendations provided are based on the images presented by the referring veterinarian. No evaluation can be communicated regarding pathology that was not visible in the image/video clips provided.**

Thank you for this referral. This report was generated using transcription software, and minor dictation errors may be present. If the clinical or image interpretation does not parallel your findings or if I can be of any further assistance, please contact me.

**Maggie Machen Lamy, DVM**  
**Diplomate of the American College of Veterinary Internal Medicine (Cardiology)**  
info@sonopath.com